Neonatal Sepsis

Undergraduate Lecture Series

Mustafa. N. Sulemanji, MD, MPH

Scanned by CamScanner

Outline

Case presentation

Neonatal Sepsis
- Definition
- Pathophysiology
- Risk Factors
- Clinical Presentation
- Work-up and Management

Neonatal Herpes
- Clinical Presentation
- Work-up and Management

Scanned by CamScanner

Case Presentation

- Male infant delivered via c/section at term, birth weight 3000gr
- Perinatal history: mother had a fever of 38^{7}, tachycardia, foul smelling liquor at time of delivery.
- Antenatal history: poor antenatal care, HIV serology negative
- APGAR: 7^{1}, 8^{5}, 9^{10}

Scanned by CamScanner

Case Presentation

- Vitals: Temp 35.8°C, HR 187 bpm, RR 78, BP 46/23 (28)
- CNS: lethargic, arousable with pain and touch
- Color: pale looking, cutis (+), delayed cap refill time, no rash
- CVS: tachycardia (+), no murmurs, blood pressure low
- Resp: respiratory distress (+), retractions (+), nasal flaring (+)
- Abdomen: Liver & Spleen are non-palpable, non tender
- Extremity: clammy, not well perfused
  - RBS: elevated
  - CBC: elevated WBC, Platelets 90,000, Hgb 16gr/dl

Scanned by CamScanner

Case Presentation – Differential Diagnosis

- Sepsis
- Meningitis
- Pneumonia
- Pneumothorax
- Congenital Heart Defect
- Intraventricular Hemorrhage
- Necrotizing Enterocolitis
- Perforated Bowel
- Excessive Blood Loss

Scanned by CamScanner

Case Presentation

- Physical exam
- Blood work:
  - CBC
  - CRP / Procalcitonin
  - Blood Culture
  - Blood gas
- Radiologic Imaging
- Lumbar puncture and serology
- IV cannula
- Send Placenta for pathology

Scanned by CamScanner

Neonatal Sepsis

- Sepsis remains a leading cause of mortality and morbidity, especially during the first five days of life and in low and middle-income countries (LMIC)

Definition:

A clinical condition

Systemic illness

Accompanied by bacteremia

1st month of life

Incidence:

1-5 per 1000 live births

ELBW infants 2% (early onset) - 36% (late onset)

Mortality is at 13 -25%

Fusch A, et al. WHO reviews 2016

Scanned by CamScanner

Neonatal Sepsis

- Sepsis remains a leading cause of mortality and morbidity, especially during the first five days of life and in low and middle-income countries (LMIC)

Definition:

A clinical condition

Systemic illness

Accompanied by bacteremia

1st month of life

Incidence:

1-5 per 1000 live births

ELBW infants 2% (early onset) - 36% (late onset)

Mortality is at 13 -25%

Fusch A, et al. WHO reviews 2016

Scanned by CamScanner

Neonatal Sepsis

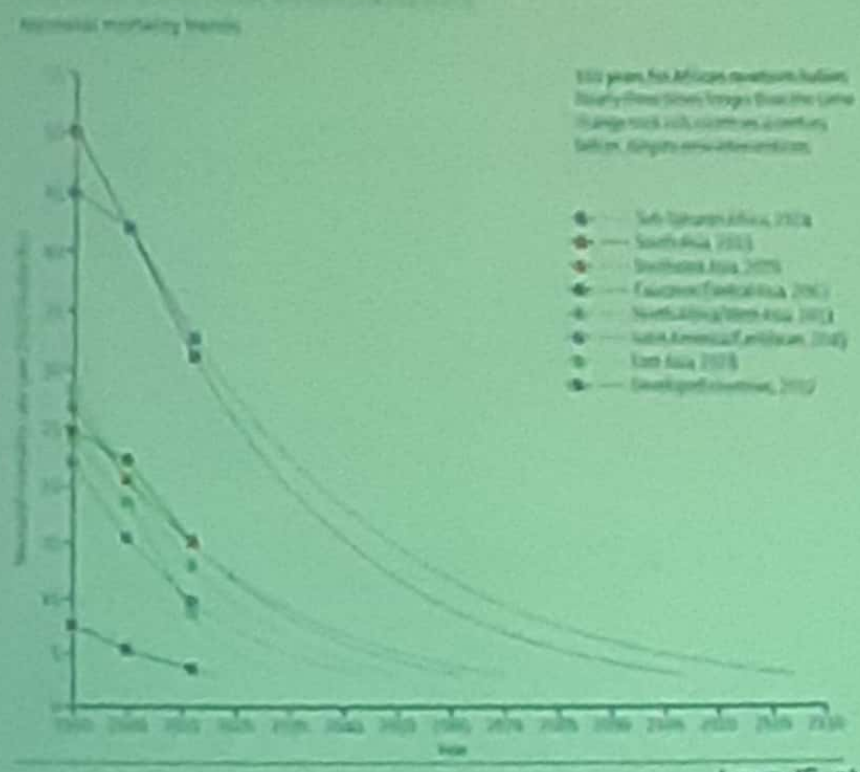

Lawn JE, et al. Lancet 2014 Jul 12;384(9938):189-205.

Scanned by CamScanner

Neonatal Sepsis

Kenya – Causes of Neonatal Mortality, 2015

In Kenya, the main causes of neonatal death in 2015 were birth asphyxia and birth trauma (31.6%), prematurity (24.6%), and sepsis (15.8%).[1]

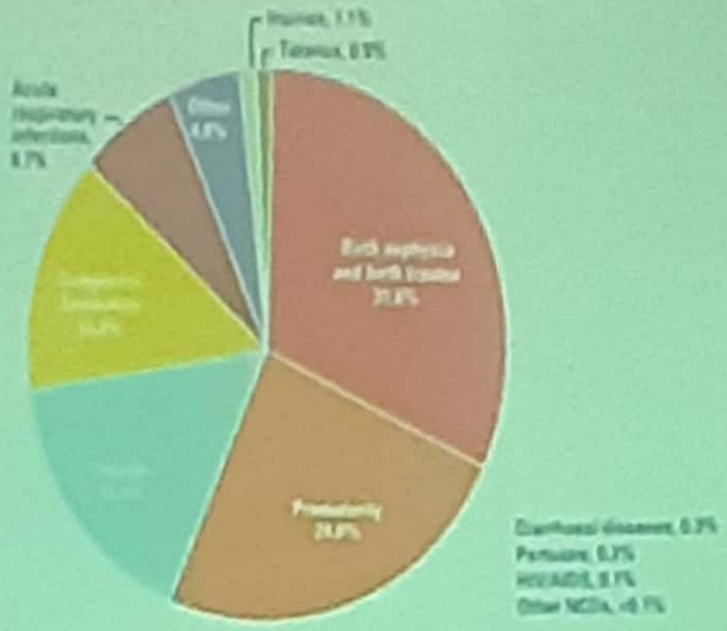

WHO-MCEE estimates for child causes of death, 2000-2015
(http://www.who.int/healthinfo/global_burden_disease/estimates_child_cod_2015/)

Scanned by CamScanner

Neonatal Sepsis

Pathophysiology:

- **Early onset sepsis**
  - Presents by 3-5 days of life
  - Antepartum or intrapartum acquisition
  - Multisystem illness, sudden onset and fulminant course
- **Late onset sepsis**
  - Presents > 5days of life
  - Insidious presentation
  - Identifiable focus
  - Vertical and Horizontal transmission

Scanned by CamScanner

Neonatal Sepsis

Clinical presentation:

- **Temperature** instability
- Change in behavior (**lethargy**, irritability)
- Skin changes (**poor perfusion**, mottling, petechiae, jaundice)
- Feeding problems (**intolerance**, emesis, **abdominal distension**)
- Cardiopulmonary changes (**respiratory distress, apnea, hypotension**)
- Metabolic changes (hypoglycemia, hyperglycemia, **metabolic acidosis, hyperkalemia**)

Scanned by CamScanner

Neonatal Sepsis

Early onset sepsis

- GBS
- E.coli and other gram – ve enteric organisms
- Listeria monocytogenes
- Streptococcus viridians, Group D strep, staph aureus
- Gram – ve bacteria (klebsiella, H. influenza, enterobacter, pseudomonas, etc)

Late onset sepsis

- CONs (S.epidermidis and S.haemolyticus)
- Staph aureus
- Enterococci
- Gram – ve organisms (E.coli, pseudomonas, Enterobacter)
- Fungal
- Viruses

K Becker. Clinic Microbiol Reviews. 2014

Scanned by CamScanner

Neonatal Sepsis

Fusch A, et al. WHO review, 2016

Scanned by CamScanner

Neonatal Sepsis

Work-up:

- Review of maternal history for risk factors
- Physical examination
- FHG (TBC/CBC) and differential[1]
- Cultures and microbiology (Urine, CSF, Secretions)
- Blood gases
- Biologic markers (CRP, procalcitonin, IL-6, IL-8)
- Radiologic imaging
- Metabolic work up (BMP, Hepatic function, lactic acid level)
- Hero score (HRV index)

1. Murphy et al: Pediatr Infect Dis J, 2012

Scanned by CamScanner

Neonatal Sepsis

Treatment:

- Antibiotic coverage
- Supportive therapy
  - Fluid resuscitation
  - Respiratory support (ventilation)
  - Cardiovascular support (fluid resuscitation, pressors)
  - Hematologic repletion (PRBC, platelets, FFP and/or Cryo)
  - Metabolic correction (euglycemia, metabolic acidosis)
  - CNS treatment (seizure control, addressing SIADH)
- Antiviral coverage
- Surgical correction
- Nutritional support

Scanned by CamScanner

Neonatal Sepsis

Antibiotic coverage:

Early onset sepsis

- combined IV aminoglycoside and expanded-spectrum penicillin
  - maternal history and risk factors
  - prevalent trends of organism colonization
  - antibiotic susceptibility
- alternative tx: IM gentamicin od and bid oral amoxicillin for 7 days.
  IM gentamicin od for 2 days and bid oral amoxicillin for 7 days.
- Cephalosporin therapy as monotherapy or in combination
- piperacillin/tazobactam

Treatment for 7-10 days may be appropriate

1. Sivanandan S et al: Int Jour Pediatr, 2011
2. Fusch A et al. WHO reviews, 2016

Scanned by CamScanner

Neonatal Sepsis

Antibiotic coverage:

Late onset sepsis

- combined IV aminoglycoside and expanded-spectrum penicillin (amoxicillin or flucloxacillin)
- combination vancomycin and gentamicin in hospitalized patients
- 3rd gen cephalosporin therapy in combination with amoxicillin/ampicillin
- piperacillin/tazobactam
- Carbapenems as mono or combination therapy

Treatment for 10-14 days may be appropriate

1. Srivanandan S et al: Int Jour Pediatr, 2011
2. Fusch A et al. WHO reviews, 2016

Scanned by CamScanner

Neonatal Sepsis

Supportive therapy:

- Fluid resuscitation: fluid bolus to support circulation, maintain urine output, prevent multi-organ injury
- Immediate transfer to an appropriate facility
- Respiratory support: to optimize oxygenation
- Cardiovascular support: fluid resuscitation, starting pressors
- Hematologic repletion: PRBC, platelets, FFP and/or cryoprecipitate
- Metabolic correction: maintain euglycemia, correcting metabolic acidosis
- CNS treatment: seizure control, addressing SIADH

Scanned by CamScanner

Neonatal Sepsis

Adjunct therapy:

Immunotherapeutic interventions

- Intravenous immunoglobulin (IVIG) infusions
- Granulocyte transfusions
- Granulocyte and granulocyte-macrophage colony-stimulating factor (G-CSF and GM-CSF)
- Pentoxifylline: anti-inflammatory properties resulting from inhibition of erythrocyte phosphodiesterase. It lowers blood viscosity and improves microcirculation and tissue perfusion [1].
- Lactoferrin: milk glycoprotein with anti-inflammatory, immunomodulatory and anti-microbial properties with a potential to prevent infections [2,3].

1. Harris E. Pediatr drug, 2010
2. Turrin CG et al. Biometals, 2014
3. Ochoa TJ. Pediatr Infect Dis J. 2015

Scanned by CamScanner

Neonatal Sepsis

Outcomes:

Overall mortality in term and late preterm infants with neonatal sepsis is ~ 2 – 4% [1].

Risk of mortality varies with [2,3]:

- Early-onset sepsis caused by *E. coli*. (6-10%)
- Infants with birth weight < 2500gr
- Type of microorganism
- Absolute neutrophil count < 1500 cells/microL
- Hypotension
- Apnea
- Pleural effusion

1. Weston EJ. Pediatr Infect Dis J. 2014
2. Stoll BJ et al. Pediatrics. 2011
3. Payne NR. Pediatr Infect Dis J. 1988

Scanned by CamScanner

Neonatal Herpes

Presentation during newborn period:

- Incidence ranges from 1 per 3000 - 20,000 live births
- Neonatal HSV has a high mortality
- More likely to be premature and SGA
- 75% of neonatal HSV is caused by HSV-2
- Symptoms are often nonspecific and may go unrecognized

Transmission can be:

- Contact with vaginal passage
- Ascending infection
- Intrauterine infection in rare cases causing congenital malformations
- Postnatal contact

Corey L and Wald A. N Engl J Med. 2009 Oct 1; 361 (14): 1376-1383

Scanned by CamScanner

Neonatal Herpes

Presentation during newborn period:

- Most babies infected with HSV are born to mothers **without** a history of HSV (75%)
- Infection following a primary genital outbreak is highest (25-60%)
- Infection following recurrent/reactivation of HSV is around 2%
- HSV can manifest itself as
  - Disseminated disease (20%)
  - Localized CNS disease (33%)
  - Disease localized to skin, eyes and mouth (SEM)
- Symptoms present **shortly after birth** (4-21days) or as late (6 wk)
- In disseminated and SEM disease, presentation is usually around 2 weeks of life

Corey L and Wald A. N Engl J Med. 2009 Oct 1; 361 (14): 1376-1385

Scanned by CamScanner

Neonatal Herpes

Risk of neonatal transmission

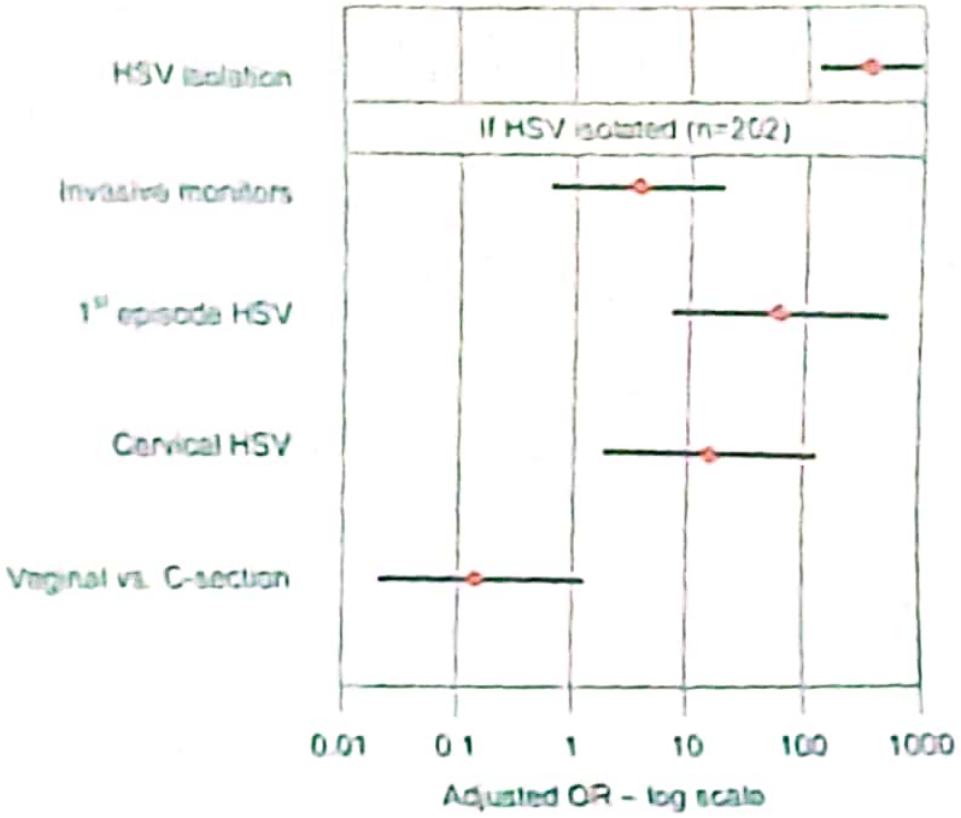

Scanned by CamScanner

Neonatal Herpes

Presentation during newborn period:

- Disseminated disease and SEM present at 10-12 days of age
- CNS disease presents at 17-19 days of age.
  - Skin vesicles, aplastic cutis, hypo/hyper-pigmentation
  - Temperature instability
  - Lethargy and Hypotonia
  - CNS manifestation: microcephaly, hydranencephaly, calcifications
  - Respiratory distress and apnea
  - Seizures and Encephalitis
  - Pneumonitis
  - Hepatitis
  - Disseminated intravascular coagulopathy (DIC)
  - Eye lesions: chorioretinitis, microphthalmia

Kohl S. Pel Ann 2002;31:726-732
Kessler AM. Paediatr Drugs 2001;3:81-90

Scanned by CamScanner

Neonatal Herpes

Laboratory workup for neonatal herpes:

- Complete blood count and differential
- Electrolytes and Liver function test
- CSF cell count, glucose and protein
- Blood and CSF cultures
- **Surface swabs** (conjunctiva, nasopharynx, rectal) for viral culture
- Skin swabs if cutaneous lesions present
- Blood and CSF HSV PCR test
- Radiologic imaging: Cranial imaging, CXR, abdominal US
- Eye examination
- EEG testing

Scanned by CamScanner